

A Honking Wookie

Tracheal Collapse in a Pomeranian

By Jill M. Patt, DVM



Introduction:

We should begin by defining a Wookie. A Wookie (with one “e”) in the sense of this article is one my 3 Pomeranian dogs named, of course, Wookie (actually Mr. Fuzz is Wookie of Sierra). Wookie is a neutered male who will be 4 years old in January 2016. He was show bred and of lovely type but early on he had to have

his hip removed and he was subsequently neutered and thus never shown. He was lovingly raised from infancy, always provided the best diet, had no traumatic injuries and has always been walked on a harness (never a collar).

Unfortunately, Wookie is also your quintessential or stereotypical Pomeranian who loves the sound of his own voice and thinks ankles of any stranger taste great. Fortunately for him, he just looks at his family with those beautiful Pomeranian eyes and we melt, so yes he too often rules the show. But because of his very reactive tendencies we did start work with Jubie & Kama Rueschenberg of Club-Doggie⁽¹²⁾ as they were one of the very few positive reinforcement trainers willing to take on this than 4 lb fur ball of storming energy that would gleefully attack a Great Dane or a Mailman. With their assistance and much training at home we were able to teach our Wookie and our other Pomeranians much more than we ever had attempted to teach a dog before. This led to some animal acting for his sister and their Facebook page “My Pom Pals”⁽⁹⁾ which is my outlet for their dozens of photos and videos.

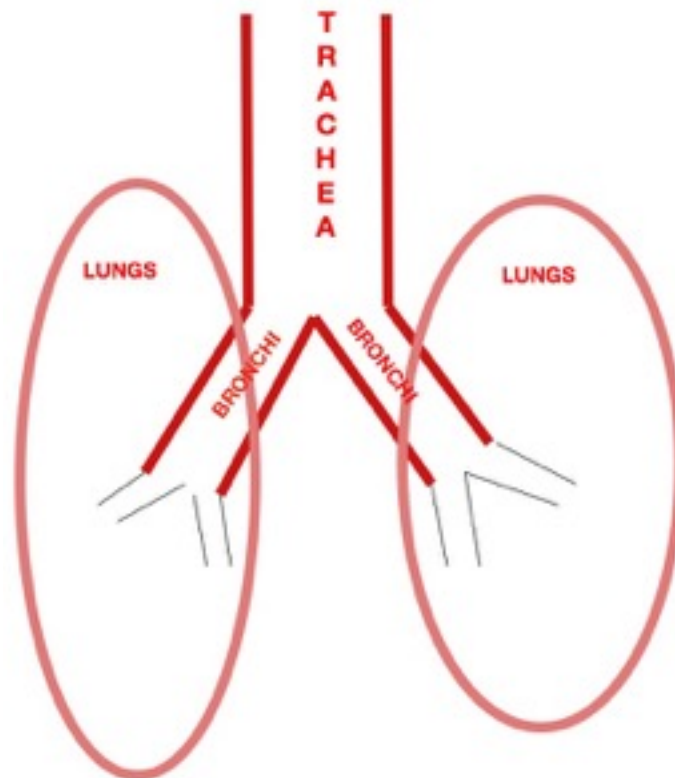
Because I post just about everything regarding the “kids” on their page, I also decided to post information and videos of Wookie’s struggles with his breathing and his eventual outcome. These posts have led to the request for a more formal article of our experiences together. So, this is Wookie’s and my story on how we managed his collapsing trachea, how decisions were made in his care and treatments selected. It delves into the various options and the personal difficulty of making these decisions for him in spite of the fact that I’m not only his mom but a veterinarian. My hope is that it will relay useful information to other owners going through this with their dogs and also share the importance of more research into this devastating disease that has no cure.

As a puppy our boy had an occasional cough that could be induced with just a gentle rub on the trachea but this was avoided with the use of a harness and was not limiting to him in any way. However, as he aged he began to exhibit the typical goose honk sound whenever he was very excited and breathing deeply. Over time the goose honk progressed to occurring during periods of non-excitement and then to actual breathing difficulties even while resting. From an owner’s perspective it felt like this escalated quickly but in reality the honking had been slowly worsening over this past year (currently 3years old).

Tracheal Collapse:

We should start with defining what is the trachea? The trachea is the main airway of the dog that delivers air from the pharynx into the primary bronchi and then

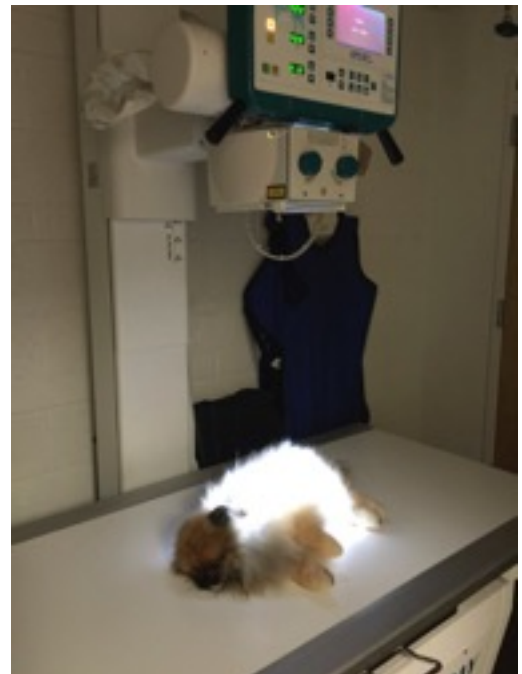into the lungs. Think of the upper airway as an upside-down Y with the single part of the Y traveling down the neck (cervical region) and into the chest (thoracic) region. The trachea then splits into 2 branches called the main stem bronchi which then branch further into ever decreasing airways that deliver air to the lungs. So the lower part of the airway system can be thought of as the branches of a tree through which the oxygen molecules travel. A breath is taken and the oxygen travels down the trunk (cervical & intrathoracic trachea) and into the main stem bronchi (first split in the tree trunk) and then down into the smaller branches that go into lung lobes above the base of the heart. The oxygen molecules continue their journey by traveling down the ever decreasing branches of the respiratory system and finally into the smallest areas where they can be absorbed into the blood system and are picked up by red blood cells and carried throughout the body for its use. For a more medical description of the trachea I encourage you to view WikiVet⁽¹⁾ which provides a nice online reference. Also see Veterinary Partner⁽²⁾ for further review.



Moving on, we need to define what occurs when a trachea collapses. And why was Wookiee honking? The dog's trachea (tree trunk) is made up of a series of cartilage based C shaped rings surrounded by muscle tissue with the open part of the C covered by a membrane on the top which allows for some stretching and expansion while breathing. I often think of the look of a dog's trachea as similar to the tubing used by an asthmatic human to breath in from a nebulizer cup with the top 1/4 of the top of the tube cut off and covered by this membrane. The honking sound is a result of the tracheal collapse. As the cartilage in the tracheal rings starts to break down or weaken, the fixed C shape starts to flatten out which causes a widening of the tracheal rings resulting in stretching of the upper membrane and eventual sagging into the interior (lumen) of the airway. When the pet takes a deep breath this sagging is exacerbated and airflow is disrupted resulting in a honking sound. Think of breathing evenly through a soft or flexible straw and than suddenly taking a deep breath. The straw would flatten and a sound would be produced similar to what is occurring during a collapsing tracheal episode.

Unfortunately, 2 things occur that result in worsening of clinical signs (cough and or honk) the first being a continuing degeneration of the dog's cartilage rings and thus more flattening making breathing even more difficult and the second is increased airway inflammation. As the turbulence of the air increases through the airway, and the sagging and pinching of the membrane continue, the inner cells lining the airway become irritated and inflamed resulting in swelling which further narrows the airway and a vicious cycle is created.

Wookiee entered into this inflammatory cycle over the summer when we noticed that his honking was occurring more frequently. We completed an initial work-up which all tracheal collapse dogs should have that included complete blood work with chest and neck x-rays. The blood work was normal and the chest x-rays were diagnostic for tracheal collapse. It is important to realize that not every collapse will be seen on chest x-rays, especially early on, as this is a dynamic thing with flattening occurring during respiration and the x-ray (or photo) may not always catch the collapse. However, in Wookiee's case collapse was clearly seen.



Medical Management:

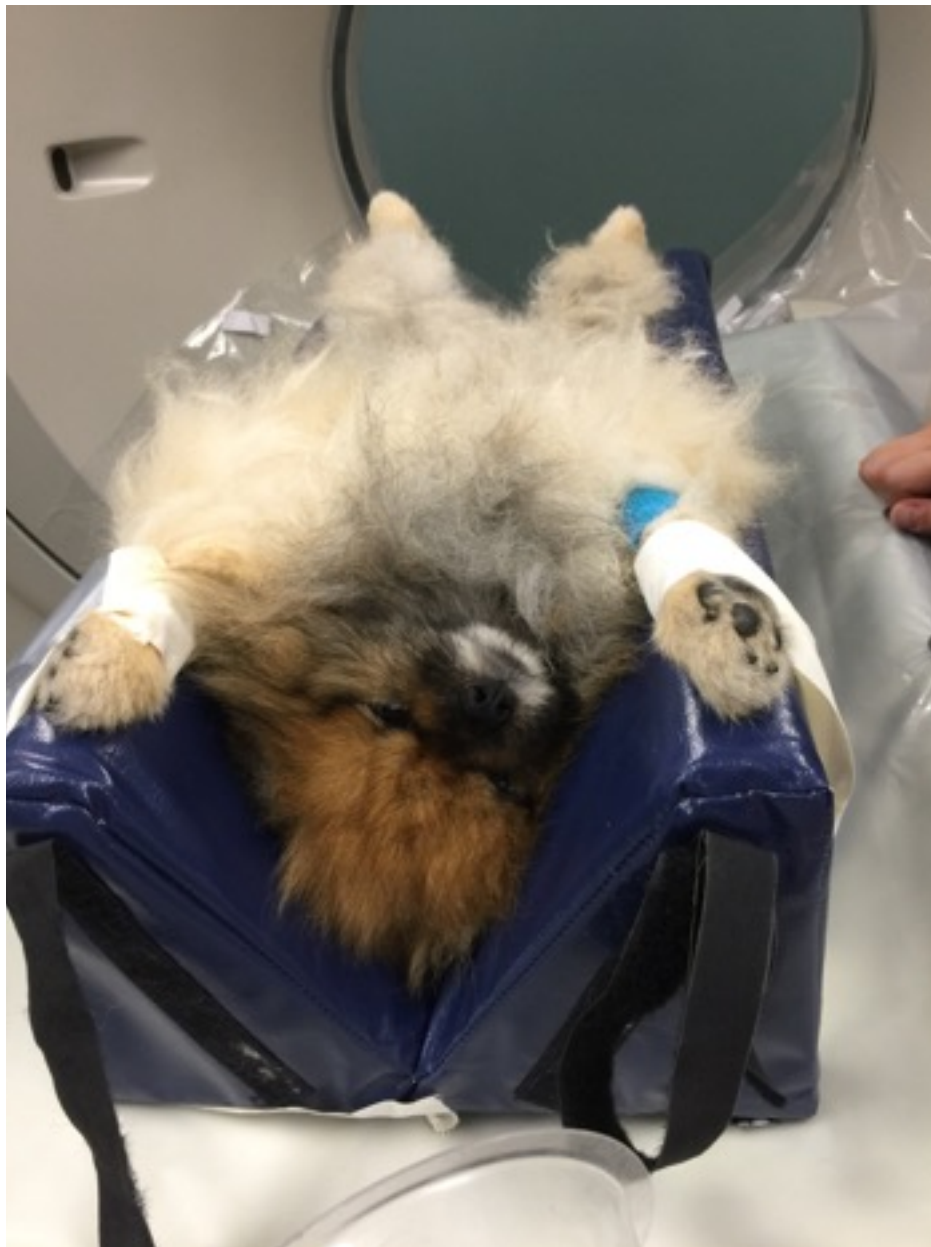Once diagnosed the first efforts made should be in reducing and eliminating exacerbating factors and in dogs this is typically obesity which is well known to worsen the degree of collapse. Medical treatment is typically approached from 3 directions 1) eliminate contributing factors such as obesity or secondary infection 2) reduction of the cough which leads to more inflammation and 3) reduction of the inflammation already in the airway.

In Wookie's case obesity was not a factor but he was placed on an even more strict diet and then we addressed the inflammation. Our first efforts at decreasing inflammation were with just the use of an anti-histamine to decrease respiratory secretions and the "stickiness" of the membrane. In Wookie's case this made no difference. He was then also placed on steroids to decrease internal swelling. Steroids are medications such as prednisone / prednisolone that are very potent anti-inflammatories but not without side effects including elevated liver enzymes, diabetes, secondary infection, weight gain and more. Therefore, this was not our first choice but became necessary in his treatment and provided him with some relief. We also had to reduce the cough and or honk and this was very difficult with Wookie due to his excited tendencies, described above, which exacerbated his breathing efforts. We opted to place Wookie on Hydrocodone Bitartrate (also called hycodan or tussigon)⁽³⁾ which is a controlled drug that is very good at controlling the cough but does also slightly sedate the dog. Lastly, we opted to place Wookie on a broad spectrum antibiotic to rule out inapparent infections. As a side note, the best way to determine if infection is present in the lower airway (lungs) is to anesthetize the pet and flush fluid into the airway and suction it back out for bacterial culture. We initially didn't want to subject Wookie to this so placed him on the trial of antibiotics but this was eventually done during his bronchoscopy.

During this time Wookie was examined and his medical therapy was directed by his internist from Desert Veterinary Medical Specialists, Dr. Melissa Riensche, a diplomate of the American College of Veterinary Internal Medicine⁽⁴⁾. His nervous mom needs to give many thanks to Dr. Riensche for all her time, attention, dedication to his care.

It should be stressed that medical therapy and controlling secondary factors are the primary means of treating tracheal collapse and that surgical intervention is reserved for those cases that prove non-responsive to all other efforts. Unfortunately, Wookie was one of these cases. In spite of aggressive medical therapy his condition worsened and he entered into a state of crisis that required

injectable sedation and emergency hospitalization in an oxygen cage. At the time of this crisis he had further diagnostics completed at VCA Animal Referral and Emergency Center of Arizona⁽⁵⁾ with Dr. Dennis Keith (Medical Director, DACVR) and Dr. Christopher Monarski (Veterinary Specialist, DACVS-SA) which included fluoroscopy (moving video x-ray) and a CT scan. Both diagnostics indicated the severity of his trachea collapse with his most narrow part of his airway only 2mm wide during an episode. We seriously considered intervention (tracheal stenting) at that time but during the course of completing the diagnostics his breathing stabilized and we opted to take him home and continue medial therapy.



Wookie's very nervous veterinarian/mom did extensive research including reading and consulting with a variety of experts in the field during this time. Unfortunately, even as a veterinarian the decision on when to intervene and which option to choose proved to be very overwhelming because there aren't any really good options for this condition.

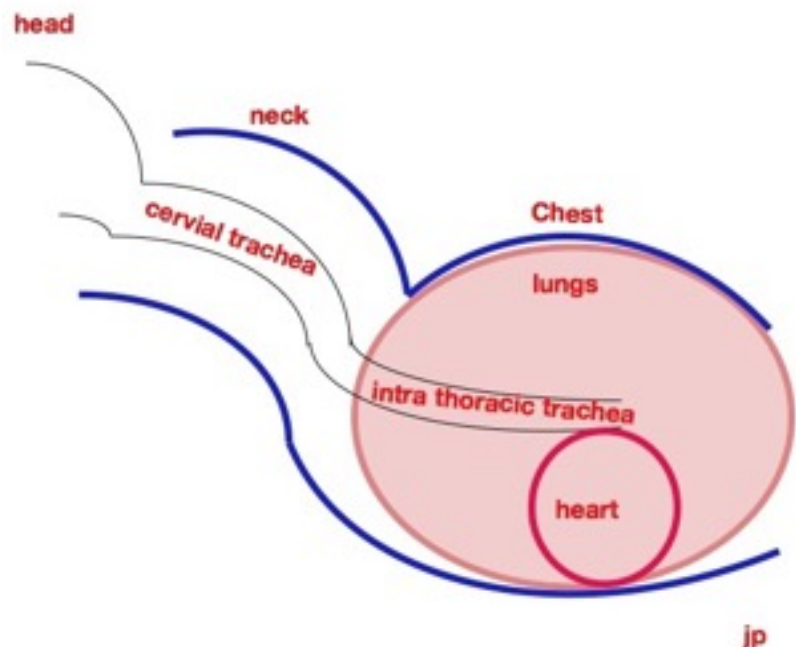
When Medical Therapy Fails:

Basically if medical therapy fails there are 3 options 1) more aggressive medical therapy such as hospitalization in oxygen and sedation, 2) external surgical ring placement and 3) intrathoracic tracheal stenting.

As stated, the problem with failure of medical management is that in my opinion there are just not other great options to truly fix this problem so both of the options (stent and ring placement) were researched and explored for Wookie.

Extraluminal Surgical Ring Placement:

The option of external ring placement is only useful for the cervical (neck) part of the trachea and the procedure involves a very complex surgery in which the surgeon dissects down to the trachea and secures external rings to help hold the trachea open in the true C shape. This should only be performed by a very experienced surgeon and even in those hands there are potential complications such as laryngeal paralysis⁽⁶⁾. In addition, this surgery is only useful for the neck (cervical) part of the collapsed trachea and not the part of the trachea within the chest. If there is collapse within the chest (thorax) the surgery is not useful. The advantages of this surgery are that nothing is placed inside the airway and the potential for a longer term successful outcome has been proven if the intrathoracic trachea remains open.



Intraluminal Tracheal Stenting:

The other option is intraluminal tracheal stenting. This involves placing a prosthetic device inside the trachea permanently to keep it open. Complications include secondary infections as the airway filter apparatus is initially disrupted, scarring around the device (granulation tissue) causing future narrowing the airway, and fracture or breaking of the stent. The advantages of this procedure include no surgical dissection required, the stent is easy to place in experienced hands and after care is less intensive with patients often going home the same or next day.

Wookie's Treatment:

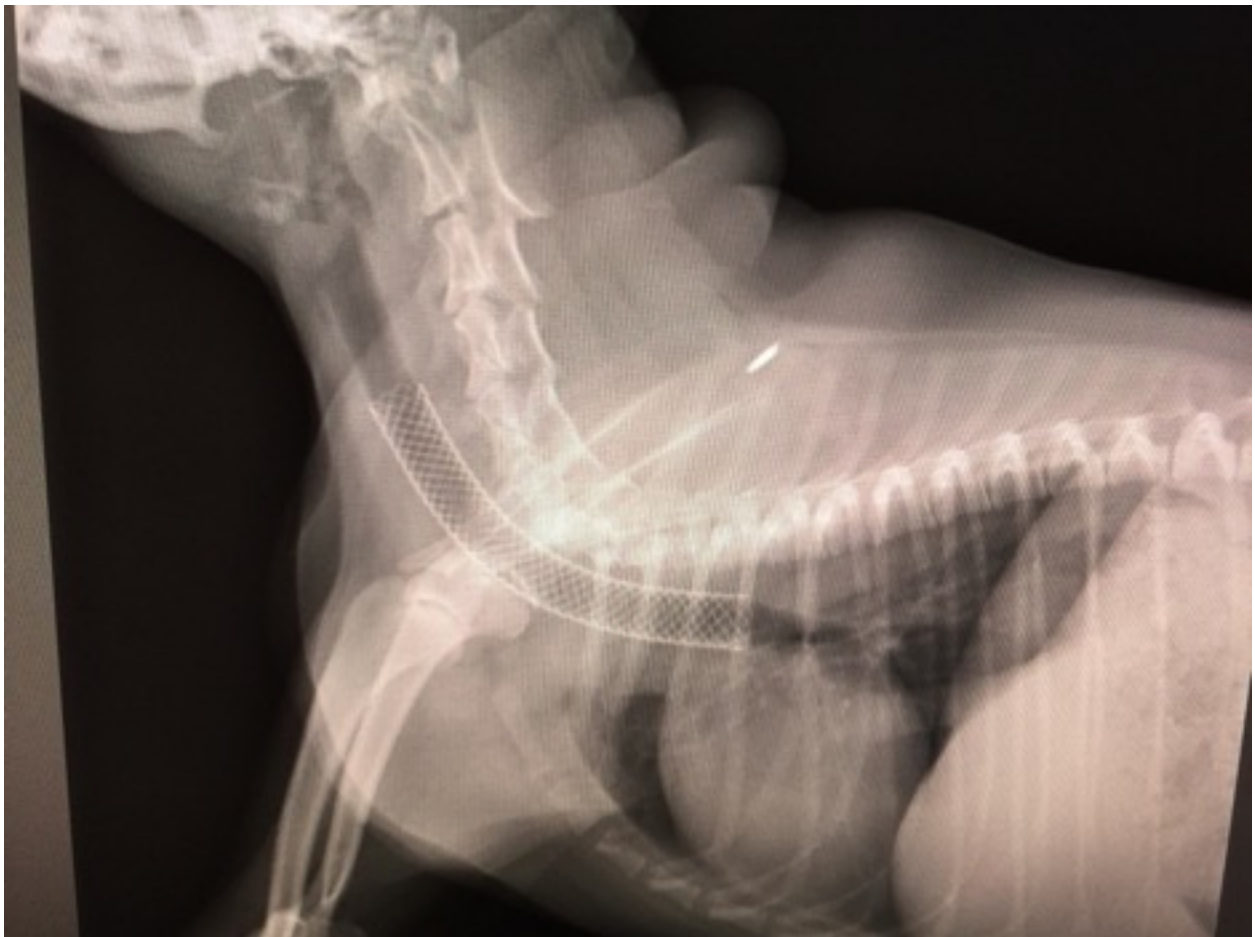After much research our choices for Wookie were as clear as mud. So what we decided to do is admit Wookie for bronchoscopy⁽¹⁰⁾ which involves general anesthesia and running a bronchoscope down into his airway to view the inside of the trachea and the opening to the bronchi. During this procedure a culture of the airway can also be done to look for hidden bacterial infections. Our decision was to consult with both a surgeon experienced at extraluminal ring placement⁽⁷⁾ and if during the bronchoscopy only cervical tracheal collapse was noted this option would be chosen. Alternatively, if more collapse was noted in the thorax than stenting would be completed by Dr. Riensche. Unfortunately or fortunately depending on the perspective Wookie had extensive collapse along his entire airway so we elected to have Dr. Riensche place an intraluminal stent.

Placement of the intraluminal stent was determined to be needed, but what type of stent and what size should we use for Wookie? While stent placement is a fairly straight forward procedure it should be done by a facility that has access to fluoroscopy⁽¹¹⁾ allowing for exact positioning of the stent within the trachea and by a specialist that is experienced at selecting the appropriate sized stent. Also the actual type of stent used is important as older stents were made of a material that often fractured over time⁽⁸⁾ and were not tapered to the conformation of the trachea. Wookie's previous CT scan helped us know the diameter of his airway but remember that he had significant swelling present so these measurements were not necessarily specific to the true size of his trachea. Generally stents are placed that are approximately 10-20%⁽⁸⁾ larger than the existing trachea size. In the past stents were only placed along the areas with visible tracheal collapse but currently most veterinarians will stent the entire airway if this is elected. Thus the end result of our decisions with Wookie was to have Dr. Riensche stent the

majority of his trachea with an Infinity brand stent⁽⁸⁾ using fluoroscopy guided placement.

Wookie's breathing was at its worst the day of the procedure and he had his consult in the morning with both the possible surgeon, Dr. Enwiller⁽⁷⁾, and internist Dr. Reinsche⁽⁴⁾. He and I then waited until they were both ready to do his procedure, as prior to the scoping we didn't know if he'd be a candidate for the surgeon's placement of the extraluminal rings so it was important to have both specialists available at the same time. While waiting in the lobby listening to his struggle to breathe, it was clear that after all the research and doubt about if and when we should intervene, the time was clearly at hand and he needed our help.

The bronchoscopy was completed and the stent was placed while he was under general anesthesia and immediately upon awakening his breathing was quiet. It was an incredible relief to not hear him struggle to breathe. He did amazingly well following the procedure and was sent home that same day.



We initially, kept Wookie very sedated and he was on a total of 11 different medications (medical therapy doesn't suddenly stop), but we have eventually weaned him down to a lower dose of prednisone, hycodan to suppress the cough and a sedative only as needed for over excitement. Our hope is to get him off the prednisone entirely and to a point where the cough medication is used only as needed. The cough suppressant is necessary following stent placement because the patients will have airway irritation due to the foreign device present in the trachea and this can cause a cough that could potentially move or dislodge the stent. Once the stent is more secure with regrowth of the normal tracheal cells the cough medicine is tapered down to an only as needed dosing.

Conclusion:

So what does the future hold for Wookie and other patients with tracheal stents? The most honest answer is that we just don't really know. The cause of trachea collapse is still a large unknown, although genetics are assumed to be involved. The newer stents have not been around a long time and every patient responds differently to a prosthesis in their trachea. What we do know is that Wookie was at a point where we had no choice but to intervene and that by having done so he is now able to breathe easily with no honking and has even begun to play a little. Our hope for him and others is that he has a long life but most importantly a life of good quality and we hope that is what we have provided him. Thank you to all his doctors that supported him and his mom during this journey and to his many supportive fans on Facebook/MyPomPals(9).

Jill M. Patt, DVM



References:

- (1) Wikivet -[https://en.wikivet.net/Trachea - Anatomy %26 Physiology](https://en.wikivet.net/Trachea_-_Anatomy_%26_Physiology)
- (2) Veterinary Partner -<http://www.veterinarypartner.com/Content.plx?P=A&S=0&C=0&A=1527>
- (3) Hycodan on Veterinary Partner- <http://www.veterinarypartner.com/Content.plx?P=A&S=0&C=0&A=519>
- (4) Desert Veterinary Medical Specialists -<http://www.dvmspecialists.com>
- (5) VCA Animal Referral and Emergency Center of Arizona - <http://www.vcaspecialtyvets.com/animal-referral-arizona/>

- (6) Article Reference: Tracheal Collapse: What Are The Options? Atlantic Coast Veterinary Conference 2012, Don R. Waldron, DVM, DACVS, Oquendo Center, Las Vegas, NV
- (7) Southwest Veterinary Surgical Services: Tara M. Enwiller, DVM, MS, Diplomate, ACVSIR:
- (8) Article Reference: Evolution of the Tracheal Stent International Veterinary Emergency and Critical Care Symposium 2013, Matthew W. Beal, DVM, DACVECC, Michigan State University, East Lansing, MI, USA
- (9) My Pom Pals - <https://www.facebook.com/mypompals>
- (10) Video of Wookie's Bronchoscopy - <https://www.facebook.com/mypompals/videos/vb.404127793045987/753012911490805/?type=2&theater>
- (11) Video of Wookie's stent placement - <https://www.facebook.com/mypompals/videos/vb.404127793045987/753015054823924/?type=2&theater>
- (12) Trainers - Club-Doggie <http://club-doggie.com/>